

## THE AETIOLOGY OF ACUTE APPENDICITIS. IS ALLERGY THE MISSING LINK? A NARRATIVE REVIEW

### A ETIOLOGIA DA APENDICITE AGUDA. SERÁ A ALERGIA O ELO PERDIDO? UMA REVISÃO NARRATIVA

 NUNO CARVALHO<sup>1,2</sup>,  FILIPE BORGES<sup>1,2</sup>,  BEATRIZ COSTA<sup>3,4,5,6,7</sup>,  PAULO COSTA<sup>1,2</sup>

<sup>1</sup> Serviço de Cirurgia Geral, Hospital Garcia de Orta, Almada, Portugal

<sup>2</sup> Faculdade de Medicina da Universidade de Lisboa, Portugal

<sup>3</sup> Serviço de Cirurgia Geral, Unidade de Cuidados Cirúrgicos Intermédios, Centro Hospitalar Universitário de Coimbra, Coimbra, Portugal

<sup>4</sup> Faculdade de Medicina de Coimbra, Portugal

<sup>5</sup> Coimbra Institute for Clinical and Biomedical Research (iCBR), Universidade de Coimbra

<sup>6</sup> Center for Innovative Biomedicine and Biotechnology (CIBB), Universidade de Coimbra

<sup>7</sup> Clinical Academic Center of Coimbra (CACC), Universidade de Coimbra

#### ABSTRACT

Acute appendicitis is the most common abdominal surgical emergency. Since the work of Fitz in the XIX century it has been assumed that luminal obstruction is the main pathological event. However, this theory has been recently challenged by some new insights that suggest that an allergic reaction can be one of the possible causes or co-factors. The current knowledge on the aetiology of acute appendicitis was reviewed in this article, with a special emphasis on allergic features.

**Key words:** *appendicitis; allergy; aetiology; hypersensitivity type 1 reaction; immune reaction; immune response.*

#### RESUMO

A apendicite aguda é a mais comum urgência cirúrgica abdominal. Desde o trabalho paradigmático de Fitz, no final do século XX, assumiu-se que a obstrução do lúmen apendicular é o principal evento patológico. Esta teoria foi questionada recentemente, pois alguns estudos sugerem que a alergia pode ser uma causa ou co-factor na etiologia da apendicite aguda. Os autores procedem a revisão da etiologia da apendicite aguda, com particular ênfase na reação alérgica.

**Palavras-chave:** *apendicite; alergia; etiologia; reação de hipersensibilidade tipo 1; reação imune; resposta imune.*

#### INTRODUCTION

The vermiform appendix has occupied a curious place in history, from an organ with an undefined biological function to an inflammatory site leading to an almost immediate surgical removal<sup>1</sup>.

In fact, acute appendicitis (AA) is the most common abdominal emergency, with an estimated lifetime risk of approximately 7% to 8% worldwide,<sup>2</sup> and the most common diagnosis requiring hospitalization of both children and adults<sup>3</sup>.



Since the original description of Reginald Fitz in 1886, little has been advanced on the subject of its aetiology<sup>4,5</sup>.

It is assumed that luminal obstruction is the main pathophysiological event that leads to appendicular inflammation. However, critical examination of the available data shows that there is little evidence of luminal obstruction being the main cause of appendicitis<sup>6</sup>. A recent study showed that fruit seeds and undigested plant residues were present in the lumen of only 0,4% of 1696 resected appendices<sup>7</sup>. In 85 appendectomies for clinical diagnosis of appendicitis, we found only 6 six luminal appendicoliths (unpublished data). It's interesting and humbling that not only a disease of such a small organ can so frequently give rise to severe and possibly fatal complications, but also that the causes of its pathology are still not fully understood<sup>8,9</sup>.

Some recent insights suggest that allergy can have an aetiologic role in AA<sup>10,11,12</sup>. The microbiota of the appendicular environment may be a co-factor which triggers the allergy and inflammation of the appendice<sup>13,14</sup>.

## OBJECTIVE

To evaluate the current knowledge on acute appendicitis aetiology, with emphasis on allergy as a possible etiological factor.

## MATERIAL AND METHOD

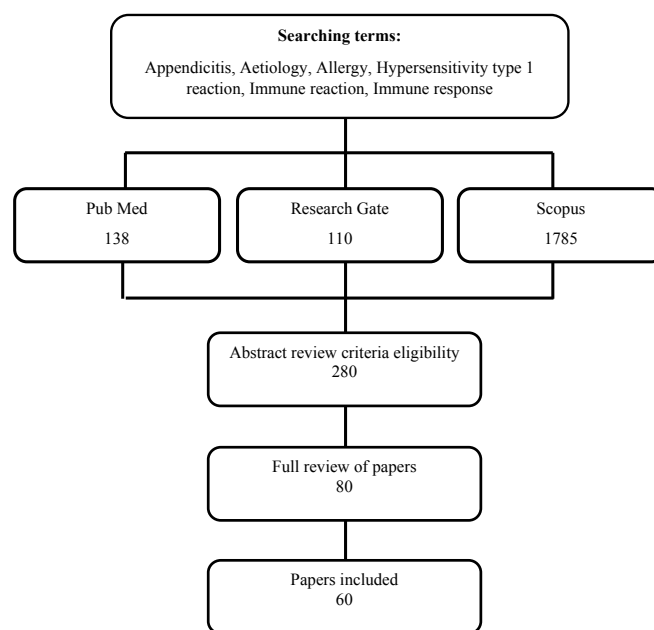
An overview was conducted using a comprehensive search strategy in the following databases: Pubmed (138), Research Gate (110) and Scopus (1785).

The search strategy included free-text terms “appendicitis, aetiology, allergy, Hypersensitivity type 1 reaction, immune reaction, immune response”. The search was made with the term appendicitis AND any other of the terms described above. The review included articles published in English, with

no restriction on the date of publication. Titles and abstracts were screened and full-text articles were obtained. Revision articles, meta-analysis and systematic reviews were also evaluated even if no mention to aetiology was present. The reference lists of the obtained articles were reviewed for further identification of potentially relevant studies. Articles not clearly addressing aetiology, with no full-text available and not written in English were excluded.

The search method resulted in 2033 articles, with 60 proving to be relevant, becoming the final list of analysed studies

FIG. 1 – Flow Chart Diagram systematic search process



## RESULTS

Based on the available evidence, it is most likely that several aetiologies can be proposed for AA. However, bacterial overgrowth in the appendicular lumen is a common feature of all the main possible hypotheses: infection, hygiene, diet, ischemia, genetics, trauma, foreign bodies, obstruction and type 1 hypersensitivity reaction<sup>6</sup>. In this review, we



TABLE 1. – Etiological factors in acute appendicitis

Aetiology	Reference	Study Design	Conclusion
Infection	Schülin <sup>13</sup>	Comparative	<i>Escherichia coli</i> predominant AA
Infection	Oh <sup>14</sup>	Comparative	<i>Campylobacter jejuni</i> predominant AA
Infection	Peeters <sup>17</sup>	Observational	Differences in microbioma
Infection	Salö <sup>21</sup>	Prospective	No differences in microbioma
Infection	Roger <sup>59</sup>	Cohort	<i>Fusobacterium</i> pathogenesis AA
Diet	Nelson <sup>27</sup>	Case-Control	Fiber intake AA same controls
Diet	Arnbjornsson <sup>28</sup>	Case-control	Fiber intake AA lower than controls
Diet	Damanik <sup>29</sup>	Cross-sectional	Positive correlation fiber intake and AA
Obstruction	Jones <sup>26</sup>	Comparative	Fecaliths more common AA
Obstruction	Wangensteen <sup>34</sup>	Experimental	Luminal obstruction dogs produce AA
Genetics	Dimberg <sup>18</sup>	Prospective	Gene morphism correlate AA histology
Genetics	Rivera <sup>30</sup>	Comparative	IL-6 gene correlate AA histology
Genetics	Murphy <sup>31</sup>	Comparative	IL-8 gene correlate AA histology
Allergy	Aravindan <sup>11</sup>	Observational	Eosinophils infiltrates in AA
Allergy	Carvalho <sup>12</sup>	Observational	Th2 cytokines are higher in AA
Allergy	Kim <sup>38</sup>	Case-Control	Increased risk appendectomy in asma
Allergy	Das <sup>51</sup>	Observational	IgE levels higher in AA
Allergy	Salö <sup>52</sup>	Cohort	IgE allergy lower risk complicated AA

AA – Acute Appendicitis

will describe the latest advances published in the literature regarding AA aetiological and pathogenic features, with emphasis on allergy. Table 1 presents the most common and relevant etiological factors in acute appendicitis.

## Infection

Although it has traditionally been stated that bacterial overgrowth in the appendix is secondary to appendicular obstruction and/or inflammation, the data supporting this concept

is surprisingly limited and the role of microbes in the pathogenesis of appendicitis is uncertain<sup>15</sup>. A microbiological cause has often been suggested, since the pathologic spectrum of AA encompasses a wide range of infectious entities, such as viral, bacterial, fungal and parasitic organisms, that can be either associated with specific histologic findings or not<sup>16</sup>. A number of microorganisms, including *Bacteroides*, *Peptostreptococcus*, *Fusobacterium*, and *Bilophila* have been isolated from appendicular cultures in AA<sup>15</sup>.

Efficacy of antibiotic therapy for AA further indicates bacterial involvement in its



pathophysiology, or at least a disorder of abnormal bacterial colonization<sup>15,17</sup>.

Recently, conservative treatment of AA without antibiotics was presented, suggesting a non-bacterial aetiology in uncomplicated appendicitis<sup>18</sup>. Also pointing against an infectious aetiology, is the fact that bacterial invasion is a later event in disease development<sup>19</sup>.

The microbial composition of the human appendix is subject to extreme

variability and comprises a diversity of biota that may play an important and as-yet-unknown role in human health<sup>20</sup>.

The appendiceal microbiome in paediatric patients with AA is highly diverse, the intraluminal microbial composition differing significantly depending on the degree of inflammation, with *Escherichia coli* being predominant in all groups<sup>13</sup>. A large prospective cohort study showed that overall composition of the faecal microbiota of patients with a recent AA and appendectomy did not significantly differ from healthy individuals, however, subtle differences were subsequent identified, confirming an association of faecal microorganisms with AA<sup>17</sup>.

The microbiome pattern was evaluated in phlegmonous, gangrenous, perforated appendicitis and control. No differences were found between groups, or correlation between inflammation grade and a specific bacteria<sup>21</sup>.

A recent study using quantitative PCR technology and 16S rRNA gene sequencing revealed that levels of *Campylobacter jejuni* DNA, unlike those of other *Campylobacter* species or pathogens tested, were significantly higher in AA samples than in samples of incidental appendectomy, indicating that *Campylobacter jejuni* may be a significant cause of AA<sup>14</sup>. Nevertheless, microbiota and appendicitis studies only showed associations, not definitive causal relations<sup>9</sup>.

Microbiology APPendicitis ACuta (MAPPAC) is a recruiting prospective multicenter trial that compares the role of microbiology and immune

response in the etiology of uncomplicated and complicated acute appendicitis that hopefully will provide new insights in the role of microbiota in AA<sup>22</sup>.

## Hygiene

This hypothesis proposes that AA is triggered by enteric infections during childhood and early adulthood, claiming that as hygiene improves, young children avoid infection and will become more vulnerable to AA later in life when exposed to enteric infections, due to the reduced immunity<sup>6,23</sup>. A recent nationwide population cohort study in Taiwan showed that children with low piped water supply were at an increased risk of appendicitis, which is contrary to the hygiene hypothesis, proving that hygiene amenities may protect children against appendicitis<sup>24</sup>.

## Diet

Diet may also be a causal factor, since AA is much more frequent in industrialized countries than in developing ones<sup>25</sup>. Low-fiber diets and higher sugar intake are possibly associated with AA<sup>17</sup>, being this disease predominantly associated with modern Western cultures and rarely seen in Africans and Indians that have a traditional lifestyle. However, its incidence increases in Africans consuming Western diets<sup>26</sup>.

AA is associated with fecaliths and, low-fiber diets consumed in developed countries lead to fecalith formation<sup>26</sup>.

Less refined carbohydrate diets ingested in European countries during both World Wars were associated with a fall in the prevalence of AA<sup>6</sup>.

A case-control study showed that low water intake was an independent risk factor for AA, while for dietary fiber the consumption was similar in cases and controls<sup>27</sup>. The results from a Swedish



case-control study support the hypothesis that diet, in particular a lack of fiber, may be an important factor in the pathogenesis of acute appendicitis<sup>28</sup>.

A cross-sectional design study showed a significant correlation between low-fiber diet with appendicitis incidence<sup>29</sup>.

## Genetics

Genetic susceptibility was proposed by several authors, being based on racial and familiar differences. However, it will be very difficult to separate genetic factors from environmental ones, like diet and others<sup>6</sup>.

Polymorphism in the IL-6 gene was associated with the severity of AA. The risk for developing appendicular perforation or gangrene may be determined, in part, by variations in the IL-6 gene<sup>30</sup>, as the nature of the inflammatory response in AA was correlated with gene expression patterns<sup>31</sup>. It has been proposed that almost half of the variability in AA's risk is attributed to genetic factors<sup>5</sup>, having recently demonstrated that the association of gene variants with risk and severity of AA suggests an etiologic role for genetic regulation of the inflammatory response<sup>18</sup>. In a study with identical twins, researchers reported no genetic effect in men, whereas a 20% hereditary effect was found in women<sup>32</sup>.

## Obstruction

The concept of obstruction as the cause of AA was described as early as 1896 in separate work by Dieulafoy and Talamon<sup>33</sup>. However, it was not until the classic work of Wangensteen in 1937, that obstruction by a fecalith (hard lump of obstructing faeces) or lymphoid tissue was thought to be the most common cause<sup>34</sup>. The mucosal secretory function of the inflamed appendix continues and without a patent lumen, this causes increased

intraluminal pressure, resulting in distension of the appendix, enteric bacterial overgrowth and infection. Simultaneously, venous outflow ceases, which is followed by loss of arterial inflow. Without arterial supply, the appendicular wall becomes ischemic and gangrenous until free wall perforation occurs<sup>19,35</sup>. In rabbit experimental models, silk ligation of the appendicular base induces rapid pathological changes, as seen in AA<sup>36</sup>.

This proposed mechanism was challenged by research showing that AA can occur in the presence of a patent lumen. Fecaliths are equally common in the population without appendicitis and intraluminal pressures are frequently normal despite AA<sup>37</sup>.

Some authors argue that obstruction is the result, rather than the cause, of appendicular inflammation<sup>6,16</sup>. Acute mucosal and submucosal inflammation has been suggested to be the main pathological cause of appendicitis. The submucosa of the human appendix is composed of a large number of lymphoid follicles. Thus, immune reactions can result in lymphoid hyperplasia and inflammation and subsequent appendicitis<sup>38</sup>. The best evidence indicates that obstruction, at least in the majority of cases, is unlikely to be the primary cause<sup>2,19</sup>.

## Type 1 Hypersensitivity reaction

The appendix is predominantly a lymphoid organ associated with the gastrointestinal tract. The possibility that an immune response to an unrecognised local antigen could be a significant factor in the pathogenesis of AA was considered by Tsuji<sup>10</sup>. He showed that the CD4 / CD8 ratio was increased and that IgA, IgM and IgG plasma cells were elevated in appendicular tissue specimens of AA. He proposed that the differential lymphocyte response could be the result of an endoluminal antigenic stimulation and a major factor in the pathogenesis of AA<sup>39</sup>.



Aravindan showed eosinophilic infiltration, muscular edema and mastocyte degranulation in appendicular specimens of AA<sup>11</sup>. These features are similar to those observed in bronchial wall in asthma and systemic anaphylaxis. He proposed that AA was a type 1 hypersensitivity reaction and that infection was a later consequence of appendicular mucosa breakdown<sup>11</sup>. Muscle contraction is a feature of allergy, the appendix behaving as a contractile chamber and appendicular wall muscle contraction leading to luminal obliteration<sup>40</sup>. This response can happen in any segment of the gastrointestinal tract, however, the appendicular lumen is much more vulnerable because of its small calibre and low tolerance for oedema, mucosal ischemia happening afterwards. In a resected ileum segment in a case of AA, a similar eosinophilic infiltration was present, demonstrating that the inflammatory process is not limited to the appendix<sup>11</sup>.

Appendicular mucosa is densely populated by resident immune cells including CD4+, CD8+ effector and regulatory T cells, antibody-secreting B cells and mononuclear phagocytes (macrophages and dendritic cells). Eosinophils are also resident cells in the normal intestinal mucosa<sup>41</sup>. All cells involved in both allergy and AA are present in the appendicular mucosa and, therefore, AA can be a consequence of antigen intolerance<sup>10,39</sup>.

The gastrointestinal tract is one of the main points of entrance of allergens into the body during life and it usually develops immunological tolerance to allergens, that are mostly present in food, although allergic reactions and food intolerance may occur in some patients. Previous studies reported increased allergic reactions in patients with appendicitis, as assessed by a skin prick test<sup>42</sup>, whereas others found no difference between positive tests of paediatric patients with AA and the control group<sup>43</sup>.

Histamine is the final effector of allergic reactions<sup>44</sup>. In 1936 Seyle experimentally induced AA in 11 out of 12 rats, with histamine injection in the jugular vein. Interestingly, no other viscera

were affected except for a small gastric erosion in one case<sup>45</sup>.

Allergy is also characterized by a powerful immunogenic response, after antigen recognition, through production of Th2 cytokines and ultimately of IgE, in conjunction with release of inflammatory mediators<sup>46</sup>.

Thelper type 2 (TH2) lymphocytes and eosinophils accumulate in inflammatory tissues. TH2 cells orchestrate the inflammatory response through the secretion of several cytokines, particularly interleukin 4 (IL-4), IL-5, IL-9 and IL-13. IL-4 is the major regulator of IgE production by B cells and is required for optimal TH2 differentiation. IL-5 is a key factor in eosinophilia. IL-9 has pleiotropic activities on allergic mediators such as mast cells, eosinophils, B cells and epithelial cells. IL-13 overlaps with IL-4<sup>47,48</sup>.

By analogy with bronchoalveolar lavage fluid, the concept of appendicular lavage fluid was developed by us to study local inflammatory reaction in AA<sup>12</sup>. A clinical study showed IL-4, IL-5 and IL-9 elevation in phlegmonous AA lavage fluids in comparison with appendectomy specimens obtained after clinical suspicion of AA, which was not histologically confirmed, therefore corroborating that AA has an allergic component<sup>12</sup>.

In allergy, antibodies are synthesized in the shock organ and their presence in the bloodstream is a consequence of the excessive local production<sup>49</sup>. IgE is found at the nasal mucosa of patients with allergic sinusitis<sup>50</sup>. Using an anti-IgE monoclonal antibody we were able to assess the presence of IgE in appendicular specimens of patients with clinical diagnosis of AA and in incidental appendectomies. IgE levels were higher in AA, as it was expected, in the presence of an allergic component during AA (Unpublished data).

IgE serum levels were determined in recurrent appendicitis, first-time acute appendicitis, histologically normal appendices and chronic asthma. Higher levels were seen in recurrent appendicitis, suggesting a type 1 hypersensitivity reaction<sup>51</sup>.





A recent cohort study of 605 children undergoing appendectomy showed that those with IgE-mediated allergy had a 3-fold lower risk of complicated appendicitis compared with those without allergy. The authors concluded that an allergic immune response modulates the severity of appendicitis. Yet they could only speculate about the causal mechanisms<sup>52</sup>.

A case-control study using a national sample cohort showed an increased risk of appendectomy in asthma patients. An allergic reaction or atopy was proposed as a plausible mechanism. Allergic reactions could accelerate inflammation and obstruction of the appendix and lead to appendicitis<sup>38</sup>.

A clear understanding of the pathological basis of appendicitis requires further investigation<sup>31</sup>. Evidence showing allergic features in AA is growing. The diagnosis of allergy in AA will be particularly difficult or impossible because there will be thousands of antigens to test<sup>53</sup>.

## DISCUSSION

Although AA has been recognized for more than 130 years, its aetiology is controversial and no real progress has been made in the last century<sup>4,5</sup>. It is believed that the primary pathogenic event in AA is luminal obstruction, resulting from a variety of causes, however, in most cases no obstruction can be found<sup>19,54</sup>.

Others factors contribute to confounding AA aetiology. Recent evidences suggest that perforated and non-perforated appendicitis are different entities, the natural history of appendicitis is not always progression to necrosis, inclusive, in some cases there is AA spontaneous regression and the relation between disease progression and time elapsed is not straight full<sup>55,56</sup>.

Several causes have been proposed, some of them are merely academic, such as foreign body, trauma or ischemia. Recent interest focused on

microbiota, but the results of the different studies are inconsistent and a definitive causal relation cannot be proposed<sup>9</sup>.

Allergic reaction can trigger an inflammation in appendicular mucosa that results in appendicular lumen obstruction, followed by the sequence of events that are classically taught<sup>157</sup>.

The allergy hypothesis is attractive, as thousands of antigens pass through the gastrointestinal tract, being some of them endogenous to the gut. Smooth muscle contraction and mucosal oedema that occur in asthma, which is the paradigm of allergic disease, can obstruct the appendicular lumen and give rise to the known physiopathology events that culminate in appendicular wall necrosis. As in asthma, the allergy can regress by itself and the obstruction resolved<sup>58</sup>. In AA, if a recanalization of the obstruction zone occurs spontaneously or as a result of antibiotic treatment, the inflammatory process may regress.

The histologic features of AA, eosinophilic infiltration, muscular edema and mastocyte degranulation are common in allergic reactions<sup>11</sup>. Clinical and experimental data clearly show that an allergic reaction, or at least an immune component, is present in AA, which is more common in atopic than in non-atopic individuals<sup>42</sup>, having asthma patients increased risk of appendectomy<sup>38</sup> and IgE-mediated allergy lowering the risk of complicated allergy<sup>52</sup>. A Th2 immune response is present in AA<sup>12</sup> and IgE levels are higher in AA than in the control group<sup>52</sup>.

AA may represent an abnormal immune response to changes in the composition of the microbiome. Appendiceal dysbiosis could be mediated by environmental factors, like low fiber content in Western diet<sup>15,59</sup>.

The confirmation of the concept of AA as an allergic reaction, or at least, an allergic component in AA, can open novel strategies for conservative treatment of AA.



## CONCLUSION

The exact pathogenesis of acute appendicitis is still unclear<sup>60</sup>. Appendicitis may represent a convergence of genetic and environmental factors, including diet and microbial colonization<sup>8</sup>.

A definitive causal relation between allergy and acute appendicitis cannot be established, but allergic features are undoubtedly present in acute appendicitis<sup>12,42,52</sup>.

The allergic component of Acute Appendicitis is a field of interest for future research that can change its treatment<sup>12</sup>.

## REFERENCES

1. Vitetta L, Chen J, Clarke S. The vermiform appendix: An immunological organ sustaining a microbiome inoculum. *Clin Sci*. 2019;133(1):1-8. doi:10.1042/CS20180956
2. Petroianu A, Villar Barroso TV. Pathophysiology of Acute Appendicitis. *JSM Gastroenterol Hepatol*. 2016;4(3):4-7.
3. Orlova E, Andrew Yeh MS et al. Genetic association and differential expression of PITX2 with acute appendicitis. *Hum Genet*. 2019;138:37-47.
4. Walker RPA, Segal I. Editorial: What causes appendicitis? *J Clin Gastroenterol*. 1990;12(2):127-129. doi:10.1097/00004836-199004000-00002
5. Ergul E. Heredity and familial tendency of acute appendicitis. *Scand J Surg*. 2007;96(4):290-292. doi:10.1177/145749690709600405
6. Carr NJ, Weldon F. The pathology of Acute Appendicitis. *Annals Diagnostic Pathology*. 2000; 4:46-58.
7. Engin O, Yildirim M, Yakan S, Coskun GA. Can fruit seeds and undigested plant residuals cause acute appendicitis. *Asian Pac J Trop Biomed*. 2011;1(2):99-101. doi:10.1016/S2221-1691(11)60004-X
8. Walker ARP, Segal I. Appendicitis: An African perspective. *J R Soc Med*. 1995;88(11):616-619. doi:10.1177/014107689508801104
9. Jackson HT, Mongodin EF, Davenport KP, Fraser CM, Sandler AD, Zeichner SL. Culture-independent evaluation of the appendix and rectum microbiomes in children with and without appendicitis. *PLoS One*. 2014;9(4). doi:10.1371/journal.pone.0095414
10. Tsuji M, McMahan G, Reen DJ, Puri P. New insights into the pathogenesis of appendicitis based on immunocytochemical analysis of early immune response. *J Pediatr Surg*. 1990;25(4):449-452. doi:10.1016/0022-3468(90)90392-M
11. Aravindan KP. Eosinophils in acute appendicitis: possible significance. *Ind J Pathol Microbiol* 40. 1997:491-498.
12. Carvalho N, Barros A, Coelho HO, Moita CF, Neves-Costa A, Pedroso D et al. A Th2 Cytokine Profile in Appendicular Lavage Fluid Suggests Allergy as a Possible Etiology for Acute Appendicitis. *Mediators Inflamm*. 2019;2019:7-11. doi:10.1155/2019/8146257
13. Schülin S, Schlichting N, Blod C, Opitz S, Suttikus A, Stingu CS et al. A comparative study. *Medicine (2017)* 96:52:e9518. doi: 10.1097/MD.00000000000009518
14. Oh SJ, Pimentel M, Leite G, Celly S, Villanueva-Millan M, Lacsina I, et al. Acute appendicitis is associated with appendiceal microbiome changes including elevated *Campylobacter jejuni* levels. *BMJ Open Gastro* 2020;7:e000412. doi:10.1136/bmjgast-2020-000412
15. Rogers MB, Brower-Sinning R, Firek B, Zhong D, Morowitz MJ. Acute appendicitis in children is associated with a local expansion of fusobacteria. *Clin Infect Dis*. 2016;63(1):71-78. doi:10.1093/cid/ciw208
16. Lamps LW. Infectious Causes of Appendicitis. *Infect Dis Clin North Am*. 2010;24(4):995-1018. doi:10.1016/j.idc.2010.07.012
17. Peeters T, Penders J, Smeeckens SP, Galazzo G, Houben B, Netea MG et al. The fecal and mucosal microbiome in acute appendicitis patients: An observational study. *Future Microbiol*. 2019;14(2):111-127. doi:10.2217/fmb-2018-0203
18. Dimberg J, Rubér MS. Genetic polymorphism patterns suggest a genetic driven inflammatory response as pathogenesis in appendicitis. *Int J Colorectal Dis*, 35, pages277-284(2020)  
<https://doi.org/10.1007/s00384-019-03473-1>
19. Wagner M, Tubre DJ, Asensio J. Evolution and Current Trends in the Management of Acute Appendicitis. *Surg Clin N Am* 98 (2018) 1005 – 1023 <https://doi.org/10.1016/j.suc.2018.05.006> surgical.theclinics.com 0039-6109/18/a 2018
20. Guinane CM, Tadrous A, Fouhy F, Ryan A, Dempsey E, Murphy B et al. Microbial composition of human appendices from patients following appendectomy. *2013mBio* 4(1):e00366-12. doi:10.1128/mBio.00366-12.
21. Salö M, Marungruang N, Roth B, Sundberg T, Stenström P, Arnbjörnsson E et al. Evaluation of the microbiome in children's appendicitis *Int J Colorectal Dis* (2017) 32:19-28 doi 10.1007/s00384-016-2639-x
22. Vanhatalo S, Munukka E, Sippola S, Jalkanen S, Grönroos J, Marttila H et al. The APPAC collaborative study group. Prospective multicentre cohort trial on acute appendicitis and microbiota, aetiology and effects of antimicrobial treatment: study protocol for the MAPPAC (Microbiology APPendicitis ACuta) trial. *BMJ Open* 2019;9:e031137. doi:10.1136/bmjopen-2019-031137





23. Barker DJP, Osmond C, Golding J, Wadsworth MEJ. Acute appendicitis and bathrooms in three samples of British children. *Br Med J (Clin Res Ed)*. 1988;296(6627):956-958. doi:10.1136/bmj.296.6627.956
24. Li HM, Liu SZ, Huang YK, Su YC, Kao CH. Risk of Appendicitis among Children with Different Piped Water Supply: A Nationwide Population-Based Study. *Int. J. Environ. Res. Public Health* 2018, 15, 1601; doi:10.3390/ijerph15081601
25. Girard-Madoux MJH, Gomez de Agüero M, Ganal-Vonarburg SC, Mooser C, Belz GT, Macpherson AJ, Vivier E. The immunological functions of the Appendix: An example of redundancy? *Semin Immunol*. 2018 Apr;36:31-44. doi: 10.1016/j.smim.2018.02.005. Epub 2018 Mar 2.
26. Jones AB, Demetriades D, Segal DB. The Prevalence of Appendiceal Fecaliths in Patients with and without Appendicitis. A comparative study from Canada and South Africa *Ann Surg*. 1985 Vol. 202:80-82.
27. Nelson M, Morris J, Barker DJP, Simmonds S. A case-control study of acute appendicitis and diet in children. *Journal of Epidemiology and Community Health*, 1986, 41, 316-318
28. Arnbjörnsson E. Acute appendicitis and dietary fiber. *Arch Surg*. 1983 Jul;118(7):868-70. doi: 10.1001/archsurg.1983.01390070076015. PMID: 6305309.
29. Damanik B, Fikri E, Pahlevi I, Nasution P. Relation between fiber diet and appendicitis incidence in children at H. Adam Malik central hospital Medan North Sumatra-Indonesia. *Bali Medical Journal (Bali Med J)* 2016, Volume 5, Number 2: 268-271
30. Rivera-Chavez FA, Peters-Hybki DL, Barber RC, et al. Innate immunity genes influence the severity of acute appendicitis. *Ann Surg*. 2004;240(2):269-277. doi:10.1097/01.sla.0000133184.10676.26
31. CG Murphy, JN Glickman KT, Tomczak K, Wang YY, Shannon MW, Horwitz BH et al. AA is characterized by a uniform and highly selective pattern of inflammatory gene expression. *Mucosal Immunol*. 2008; Vol 1 N4:297-308.
32. Kim SY, Min C, Oh DJ, Choi HG. Increased risk of appendectomy due to appendicitis after tonsillectomy in women: A longitudinal follow-up study using a national sample cohort. *Medicine (Baltimore)*. 2019;98(19):e15579. doi:10.1097/MD.00000000000015579
33. Hennington MH, Tinsley EA Jr, Proctor HJ, Baker CC. Acute appendicitis following blunt abdominal trauma. Incidence or coincidence? *Ann Surg*.: 1990; 214(1): 61-63. doi: 10.1097/00000658-199107000-000.
34. Wangenstein OH, Bowers WF. Significance of the obstructive factor in the genesis of acute appendicitis. *Arch Surg* 1937;34:496-526. 10.1001/archsurg.1937.01190090121006
35. Baird DLH, Simillis C, Kontovounisios C, Rasheed S, Tekkis PP. Acute appendicitis. *BMJ*. 2017;357:j1703. doi:10.1136/bmj.j1703
36. Katz E, Hana R, Jurim O, Pisuv G, Gutman A, Durst AL. Experimental model of acute appendicitis in the rabbit with determination of leucine amino peptidase (LAP) and acid phosphatase (Acid-P) activities in portal blood samples. *J Surg Res*. 1990;48(3):230-236. doi:10.1016/0022-4804(90)90218-Q
37. Sellars H, Boorman P. Acute appendicitis. *Surg (United Kingdom)*. 2017;35(8):432-438. doi:10.1016/j.mpsur.2017.06.002
38. Kim SY, Oh DJ, Park B, Park I-S, Choi HG. Increased risk of appendectomy in patients with asthma. *Medicine (Baltimore)*. 2019;98(38):e17203. doi:10.1097/md.00000000000017203
39. Tsuji M, Puri P, Reen DJ. Characterization of the local inflammatory response in appendicitis *J Pediatr* 1993; 16 (1):43-8
40. Baggot MG. Aseptic appendicitis, exemplifying the Universal Disorder, namely muscular and endocameral hypertension, which initiates various secondary diseases including infections. *Med Hypotheses*. 1999;53(5):429-431. doi:10.1054/mehy.1998.0789
41. Berin MC, Sampson HA. Mucosal immunology of food allergy. *Curr Biol*. 2013;23(9):R389-R400. doi:10.1016/j.cub.2013.02.043
42. Harlak A, Gulec M, Menten O, Kilbas Z, Onguru O, Acikel C et al. Atopy is a risk factor for acute appendicitis? A prospective clinical study. *J Gastrointest Surg*. 2008;12(7):1251-1256. doi:10.1007/s11605-008-0511-1
43. Cevizci MN, Sogut A, Cayir A, Demir M, Ozman SA, Erdoğan F. The Place of Atopy in the Aetiology of Acute Appendicitis in Children. *West Indian Med J* 2016; 65 (2): 287
44. O'Brien RM. Skin prick testing and in vitro assays for allergic sensitivity. *Aust Prescr*. 2002;25(4):91-93. doi:10.18773/austprescr.2002.077
45. Selye H. Acute Phlegmognous appendicitis produced by intravenous administration of histamine. *Lancet*. 1929:1210-1211.
46. Shakib F, Ghaemmaghami AM, Sewell HF. The molecular basis of allergenicity. *Trends Immunol*. 2008;29(12):633-642. doi:10.1016/j.it.2008.08.007
47. Renauld JC. New insights into the role of cytokines in asthma. *J Clin Pathol*. 2001;54(8):577-589. doi:10.1136/jcp.54.8.577
48. M. Yazdanbakhsh, Biggelaar A, Maizels R. "Th2 responses without atopy: immunoregulation in chronic helminth infections and reduced allergic disease," *Trends in Immunology*, 2001 vol. 22, no. 7, pp. 372-377.
49. Ohashi Y, Nakai Y, Kuroki K, Nakata J, Maruoka K, Ikeoka H et al. Topical immunology of nasal allergy and mucosal IgE antibodies. *Arch Otorhinolaryngol*. 1985;241(2):169-174. doi:10.1007/BF00454351
50. Kleinjan A, Vinke JG, Severijnen LWF, Fokkens WJ. Local production and detection of (specific) IgE in nasal B-cells and plasma cells of allergic rhinitis patients. *Eur Respir J*. 2000;15(3):491-497. doi:10.1034/j.1399-3003.2000.15.11.x



51. Das DN, Thomas DS, Aravindan DK. Morphology and Serum IgE Levels in Recurrent Acute Appendicitis. *Int J Adv Res.* 2016;4(10):855-859. doi:10.21474/ijar01/1869
52. Salö M, Gudjonsdottir J, Omling E, Hagander L, Stenström P. Association of IgE-Mediated Allergy with Risk of Complicated Appendicitis in a Pediatric Population. *JAMA Pediatr.* 2018;172(10):943-948. doi:10.1001/jamapediatrics.2018.1634
53. Hamilton RG. Clinical laboratory assessment of immediate-type hypersensitivity. *J Allergy Clin Immunol.* 2010;125(2 SUPPL. 2):S284-S296. doi:10.1016/j.jaci.2009.09.055
54. Bernstein L. S., Surick B., Leitman I. M. Is acute appendicitis in the weather forecast? *The Journal of Surgical Research.* 2013;185(1):e23-e25. doi: 10.1016/j.jss.2012.08.022.
55. Rubér M, Andersson M, Petersson BF, Olaison G, Andersson RE, Ekerfelt C Systemic Th17-like cytokine pattern in gangrenous appendicitis but not in phlegmonous appendicitis. *Surgery.* 2010;147(3):366-372. doi: 10.1016/j.surg.2009.09.039.
56. Rubér M, Berg A, Ekerfelt C, Olaison G, Andersson RE. Different cytokine profiles in patients with a history of gangrenous or phlegmonous appendicitis. *Clinical and Experimental Immunology.* 2006;143(1):117-124. doi: 10.1111/j.1365-2249.2005.02957.x
57. Levin MD. Pathogenesis of acute appendicitis: review. *Gastroenterol Hepatol Open Access.* 2019;10(6):279-285. doi: 10.15406/ghoa.2019.10.00396
58. Barnes PJ. Pathophysiology of asthma *Eur Respir Mon*, 2003, 23, 84-113.
59. Rogers MB, Brower-Sinning R, Firek B, Zhong D, Morowitz MJ. Acute Appendicitis in Children Is Associated With a Local Expansion of Fusobacteria. *Clin Infect Dis.* 2016 Jul 1;63(1):71-78. doi: 10.1093/cid/ciw208. Epub 2016 Apr 7. PMID: 27056397.
60. Almaramhy HH. Acute appendicitis in young children less than 5 years: review article. *Ital J Pediatr.* 2017;43:1-9. doi:10.1186/s13052-017-0335-2

**Correspondência:**

NUNO CARVALHO

e-mail: nunomdcarvalho1964@gmail.com

**Data de recepção do artigo:**

01/11/2021

**Data de aceitação do artigo:**

09/12/2021

