

## CAROLI'S DISEASE IN ADULTHOOD – A CASE REPORT

### DOENÇA DE CAROLI NO ADULTO – RELATO DE UM CASO CLÍNICO

 Urânia FERNANDES<sup>1</sup>, Ricardo Vaz PEREIRA<sup>1</sup>,  Rita MARQUES<sup>1</sup>,  João PINTO-DE-SOUSA<sup>1</sup>

<sup>1</sup> Department of Surgery, Centro Hospitalar de Trás-os-Montes e Alto Douro, Vila Real, Portugal

Correspondence: Urânia Fernandes (ufernandes@chtmad.min-saude.pt)

Received: 07/04/2022

Accepted: 01/02/2023

Published online: 03/01/2023

#### ABSTRACT

Caroli's disease (CD) is a rare congenital disorder defined by multifocal segmental dilatation of intrahepatic bile ducts. It may cause severe, life-threatening cholangitis hepatobiliary degeneration or even cancer. A 63-years-old male with monolobar CD managed with conservative treatment is presented with revision of literature. The patient presented in the emergency department with a six-hour history of cholic epigastric pain with dorsal irradiation and a normal physical exam. Past medical history included colonic polyposis, Chronic Obstructive Pulmonary Disease (COPD) and Benign Prostatic Hyperplasia. Investigation revealed infracentimetric left cystic dilatation of intrahepatic bile ducts suggestive of Caroli's disease. Despite its rare incidence, CD should be considered in patients with recurrent cholangitis. The diagnosis of CD relies mostly on imaging studies. Treatment should be customized and multi-disciplinary.

**Keywords:** *caroli disease, cholangiocarcinoma, bile duct neoplasms, abdominal pain.*

#### RESUMO

A doença de Caroli é um distúrbio congénito raro definido por dilatação segmentar multifocal dos ductos biliares intra-hepáticos. Pode causar colangite grave, degeneração hepatobiliar com risco de vida ou até mesmo cancro. Um homem de 63 anos com doença de Caroli monolobar tratado com tratamento conservador é apresentado com revisão da literatura. O doente deu entrada no serviço de urgência por dor epigástrica cólica, com 6 horas de evolução, com irradiação dorsal e exame físico normal. A história médica pregressa incluía polipose cólica, doença pulmonar Obstrutiva crónica e hiperplasia benigna da Prostata. A investigação clínica revelou dilatação cística infracentimétrica das vias biliares intra-hepáticas à esquerda sugestiva de doença de Caroli. Apesar de ter uma incidência rara, a doença de Caroli deve ser considerada em doentes com colangite recorrente. O diagnóstico de doença de Caroli baseia-se principalmente em estudos de imagem. O tratamento deve ser personalizado e multidisciplinar.

**Palavras-chave:** *doença de caroli, colangiocarcinoma, neoplasias das vias biliares, dor abdominal.*



## INTRODUCTION

Caroli's disease (CD) is a rare congenital disorder within the spectrum of ductal plate malformation characterized by multifocal segmental dilatation of intrahepatic bile ducts. Given its scarcity, epidemiology is inaccurate but the incidence is approximately 1 case per 1000000 people. The disease can be divided in two types: type I consisting of pure cystic dilatation of the intrahepatic bile ducts, whereas type II, also known as Caroli's syndrome (CS), is associated with hepatic fibrosis. CD usually presents as recurrent cholangitis with no specific signs or symptoms, and therefore as a challenging diagnosis<sup>1</sup>.

## CASE REPORT

A 63-years-old male presented in the emergency department with a six-hour history of cholic epigastric pain, with dorsal irradiation. Past medical history included colonic polyposis, Chronic Obstructive Pulmonary Disease (COPD) and Benign Prostatic Hyperplasia. The patient referred previous similar self-limited episodes. He was anicteric and normothermic. His blood pressure and heart rate were within normal range. On palpation presented with epigastric and right upper quadrant pain without peritoneal irritation signs and without hepatomegaly.

Laboratory results revealed elevation of inflammatory parameters and liver enzyme elevation but without hyperbilirubinemia, hyperamylasemia nor hyperlipasemia. Abdominal Sonography revealed infracentimetric cystic lesion in left lobe with ipsilateral ectasia of intrahepatic biliary tree, choledochal dilation (12mm) and alithiasic thickened gallbladder. Abdominal Computed Tomography (CT scan) revealed dilation of left intrahepatic bile ducts and no evidence of lithiasis. He was admitted to the ward for further investigation and pain management. Magnetic Resonance

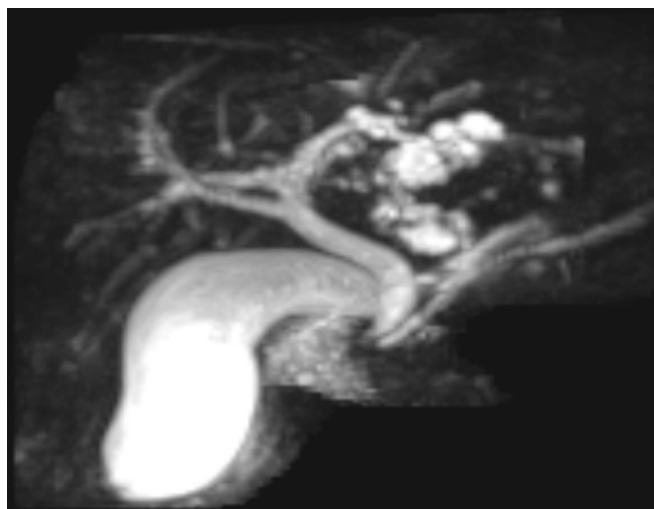


FIGURE 1 – MRCP image demonstrating infracentimetric left cystic dilatation of intrahepatic bile ducts suggestive of Caroli's disease

Cholangiopancreatography (MRCP) confirmed dilatation of intrahepatic bile ducts mainly of the left hepatic lobe and main bile duct as well as a nodular thickening of the second portion of duodenum (D2) suggestive of ampulloma. Endoscopic Retrograde Cholangiopancreatography (ERCP) identified D2 deformity, off-centered papilla which biopsy was negative for dysplasia. The patient was discharged after remission of symptoms (day seven). Further investigation reported both carcinoembryonic antigen marker (CEA) and cancer antigen 19-9 negative and upper endoscopy and endoscopic ultrasound showed no alterations. A subsequent MRCP failed to demonstrate duodenal lesion, demonstrating infracentimetric left cystic dilatation of intrahepatic bile ducts suggestive of Caroli's disease (figure 1).

No specific treatment was necessary due to the complete resolution of the acute clinical condition.

Patient remained asymptomatic for the last three years. Abides to annual consult, MRCP and laboratory tests and the indolent course has justified the diagnosis of mild Caroli's disease and therefore an expectant attitude.



## DISCUSSION

CD was first described in 1958 by Jacques Caroli<sup>2</sup> and it is a rare congenital disorder, with autosomally recessive inheritance characterized by embryologic malformation of the ductal plate. It is associated with disruption of the PKHD1 gene and subsequently of fibrocystin expressed in kidney, liver and pancreas.

CD is defined as mono or bilobar segmental saccular or fusiform dilatation of the medium and large-sized intrahepatic bile ducts<sup>3</sup>. Given its scarcity, epidemiology is inaccurate but the incidence is approximately 1 case per 1000000 people<sup>1</sup>.

In cases of monolobar disease, for unknown reason, the left lobe is more frequently affected. It is usually diagnosed during childhood but may be diagnosed in adulthood without gender predominance. The disease can be divided in two types: type I consisting of pure cystic dilatation of the intrahepatic bile ducts, whereas type II, also known as Caroli's syndrome, is associated with hepatic fibrosis. Patients who present with symptoms of CD before the age of 40 years are more likely to have type II than type I. Type II, or complex CD or CS is more frequent than type I and it is associated with hepatic fibrosis and in extreme with cirrhosis, portal hypertension and its sequels. Hence carries higher risk of cholangiocarcinoma (7%)<sup>1</sup>.

The clinical setting of CD is defined by right upper quadrant pain, fever and jaundice, all non-pathognomonic. CD predisposes to biliary stasis, resulting in intrahepatic lithiasis and possible septic complications including recurrent episodes of cholangitis, liver abscesses, septicemia and ultimately secondary biliary cirrhosis<sup>1</sup>.

Laboratory tests are non-specific, ranging from mild cholestasis to severe hepatic failure, with virtually no difference amongst the two types, besides cytopenia (more likely in type II patients)<sup>3</sup>. A liver biopsy is not required to diagnose CD, although hepatic fibrosis in CS is a histologic diagnosis. Therefore, diagnosis of CD relies mostly on imaging studies and demands the demonstration

of communications between the cysts and biliary tree<sup>1,3</sup>.

The use of non-invasive methods as abdominal ultrasound (US) is shortcomed in differentiating from other liver cysts (such as polycystic liver disease), whereas abdominal CT scan and MRCP can demonstrate enhanced fibrovascular bundles along the margins of dilated ducts, known as the central dot sign characteristic in CD.<sup>1,3</sup> MRCP or ERCP are valuable options to diagnose CD and can aid assess fusiform dilatations of the biliary tree<sup>3</sup>.

The first may show the connections between the saccular ectasias and the normal biliary tract, and exclude other causes, whereas the last has both a diagnostic potential as also a therapeutic one. Regardless, it is an invasive method that bears risk of infection and should not be used whenever the diagnosis is already established<sup>1</sup>.

Some of differential diagnosis of Caroli's disease includes Primary Sclerosing Cholangitis (PSC), recurrent pyogenic cholangitis, hepatic cysts, Autosomal-Dominant Polycystic Liver Disease (ADPLD), choledochal cysts and biliary hamartomas. Isolated fusiform ductal dilatation of PSC can be distinguished from the saccular and segmental dilation of CD. The hepatic cysts of ADPLD differ from CD because they rarely communicate with the bile ducts, are multiple, homogeneous and hypodense cystic lesions without enhancement on contrast-enhanced images. CD has the same clinical manifestations of recurrent pyogenic cholangitis but can be distinguished by the characteristic saccular dilatation of the intrahepatic bile ducts. CD corresponds to type V of congenital bile duct cysts according to the Todani et al classification<sup>4</sup> and differs from the other types because usually does not involve common bile duct. Hepatic cysts are outside the biliary tree and show no enhancement of its wall or content. Biliary hamartomas appear as tiny multiple hypodense cystic hepatic nodules with irregular borders which do not communicate with the biliary tree<sup>5</sup>.



Treatment aims to decrease morbidity and mortality associated with recurrent cholangitis, hepatic abscesses and cholangiocarcinoma<sup>6</sup>. It can be divided in two sectors: acute clinical setting, resorting to both supportive treatment and drainage procedures with Percutaneous Trans-Hepatic Cholangiography (PTHC) or ERCP or treatment of the illness per se. Either way, treatment should be customized and multi-disciplinary, including endoscopic, radiological and surgical approaches<sup>3</sup>. Surgical treatment is indicated when there is failure of conservative treatment, suspected malignancy, or symptoms associated with chronic hepatic fibrosis<sup>7</sup>. Surgical options range between less extensive (segmental or lobar hepatic resection) against more extensive (liver transplantation) depending on the extent of the disease and liver failure. In 20% of patients with localized disease managed with less extensive surgery, further radiologic or endoscopic options may be required to the contralateral hemi liver<sup>3</sup>. In extreme, liver transplantation is indicated in multilobar disease, early cholangiocarcinoma or portal hypertension. CS can be managed conservatively, despite being demanding, but liver transplantation seems to be the optimal management option in patients with portal hypertension and/or end-stage liver disease<sup>8</sup>.

Nevertheless, survival after liver transplant in patients with CS or those with cholangitis at the time of the transplant is discouraging, enhancing the importance of optimal surgical indication. In general, prognosis is volatile depending on the disease extension and symptomatic recurrence. Some authors advocate prophylactic liver resection even in asymptomatic patients with monolobar

CD. At the end of the day, surgical morbidity and malignancy risk must be balanced in the management of CD<sup>1</sup>.

Revising the literature, there are few described cases of stabilized CD with conservative treatment<sup>9,10</sup>. Nevertheless, most case reports of monolobar CD were managed with resection of affected lobe or hemi liver, with an acceptable rate of morbidity, although there was no evidence of malignancy in most cases<sup>11-14</sup>.

This case report is about a mild form of CD, justified by the indolent course. It is paramount to highlight the previous similar episodes of abdominal pain, the non-specific results of laboratory tests and the importance of serial imaging for the diagnosis. Moreover it is interesting to verify the association between colonic polyposis and CD, a possible link already described in other report<sup>15</sup>. The patient remains asymptomatic after 3.5 years of follow-up, empowering our surveillance strategy.

## CONCLUSION

CD is a rare congenital disorder defined by multifocal segmental dilatation of intrahepatic bile ducts. It may cause severe, life-threatening cholangitis, hepatobiliary degeneration or even cancer. Despite its rare incidence, CD should be considered in patients with recurrent cholangitis. The diagnosis of CD relies mostly on imaging studies. Treatment can be divided in two sectors: drainage procedures in the acute clinical setting or treatment of the illness per se. Either way, it should be customized and multi-disciplinary, including endoscopic, radiological and surgical approaches.



## REFERENCES

1. Wang ZX, Li YG, Wang RL, Li YW, Li ZY, Wang LF, Yang HY, Zhu Y, Wang Y, Bai YF, He TT, Zhang XF, Xiao XH. Clinical classification of Caroli's disease: an analysis of 30 patients. *HPB (Oxford)*. 2015 Mar;17(3):278-83. doi: 10.1111/hpb.12330. Epub 2014 Oct 19. PMID: 25327281; PMCID: PMC4333791.
2. Caroli J, Soupault R, Kossakowski J, Plocker L, Paradowska. [Congenital polycystic dilation of the intrahepatic bile ducts; attempt at classification]. *La semaine des hopitaux : organe fonde par l'Association d'enseignement medical des hopitaux de Paris*. 1958;34(8/2):488-95/sp.
3. Moslim MA, Gunasekaran G, Vogt D, Cruise M, Morris-Stiff G. Surgical Management of Caroli's Disease: Single Center Experience and Review of the Literature. *J Gastrointest Surg*. 2015 Nov;19(11):2019-27. doi: 10.1007/s11605-015-2918-9. Epub 2015 Aug 25. PMID: 26302876.
4. Todani T, Watanabe Y, Narusue M, Tabuchi K, Okajima K. Congenital bile duct cysts: Classification, operative procedures, and review of thirty-seven cases including cancer arising from choledochal cyst. *Am J Surg*. 1977 Aug;134(2):263-9. doi: 10.1016/0002-9610(77)90359-2. PMID: 889044.
5. Zhang DY, Ji ZF, Shen XZ, Liu HY, Pan BJ, Dong L. Caroli's disease: a report of 14 patients and review of the literature. *J Dig Dis*. 2012 Sep;13(9):491-5. doi: 10.1111/j.1751-2980.2012.00619.x. PMID: 22908976.
6. Hassan Seddik HB, Brahim Aitbihi, Tarik Adioui, Hanane Massit, Ahmed Benkirane. Monolobar caroli's disease: report of three cases. *International Journal of Gastroenterology, Hepatology, Transplant & Nutrition*. 2017(2(i)):23-5. <http://journal.pghtml.com/wp-content/uploads/2017/04/06-Monolobar-Carolis-disease.pdf>
7. Bockhorn M, Malagó M, Lang H, Nadalin S, Paul A, Saner F, Frilling A, Broelsch CE. The role of surgery in Caroli's disease. *J Am Coll Surg*. 2006 Jun;202(6):928-32. doi: 10.1016/j.jamcollsurg.2006.02.021. Epub 2006 Apr 21. PMID: 16735207.
8. Lai Q, Lerut J. Proposal for an algorithm for liver transplantation in Caroli's disease and syndrome: putting an uncommon effort into a common task. *Clin Transplant*. 2016 Jan;30(1):3-9. doi: 10.1111/ctr.12640. Epub 2015 Oct 19. PMID: 26385435.
9. Duvnjak M, Supanc V, Virović L, Tomasić V, Dojcinović B. [Caroli's disease]. *Acta medica Croatica : casopis Hrvatske akademije medicinskih znanosti*. 2003;57(3):249-52.
10. Boyle MJ, Doyle GD, McNulty JG. Monolobar Caroli's disease. *Am J Gastroenterol*. 1989 Nov;84(11):1437-44. PMID: 2683744.
11. Dicasillati R, Cantaluppi G, Mezzetti M. [Caroli's disease. A case report]. *Minerva chirurgica*. 2002;57(1):81-5.
12. Gillet M, Favre S, Fontolliet C, Halkic N, Manton G, Heyd B. [Monolobar Caroli's disease. Apropos of 12 cases]. *Chirurgie; memoires de l'Academie de chirurgie*. 1999;124(1):13-8; discussion 8-9.
13. Giovanardi RO. Monolobar Caroli's disease in an adult. Case report. *Hepatogastroenterology*. 2003 Nov-Dec;50(54):2185-7. PMID: 14696493
14. Jarry J, Leblanc F, Saric J. [Monolobar Caroli disease]. *Presse medicale (Paris, France : 1983)*. 2010;39(7-8):847-8. <https://www.ncbi.nlm.nih.gov/pmc/articles/PMC2727094/>
15. Hodgson SV, Coonar AS, Hanson PJ, Cottrell S, Scriven PN, Jones T, Hawley PR, Wilkinson ML. Two cases of 5q deletions in patients with familial adenomatous polyposis: possible link with Caroli's disease. *J Med Genet*. 1993 May;30(5):369-75. doi: 10.1136/jmg.30.5.369. PMID: 8391580; PMCID: PMC1016370.

