

Gut mediated syncope

Síncope de causa intestinal

Pedro Azevedo¹, Marta Custódio², Carolina Sequeira², Anabela Salgueiro Marques³

¹ Interno do Ano Comum

² Interno Formação Específica em Medicina Interna

³ Assistente Graduada Medicina Interna

Hospital de Cascais Dr. José de Almeida, Serviço de Medicina Interna

RESUMO

O tumor do estroma gastrointestinal (GIST) é um tumor mesenquimatoso, de ocorrência rara (0,1-3% de todos os tumores gastrointestinais), sendo mais vezes diagnosticados no estômago e intestino delgado. Na maioria dos casos, o GIST é causado por uma mutação com ganho de função do gene *KIT*, originando uma proliferação anormal de células intersticiais de Cajal. Reportamos o caso de um homem de 74 anos, com antecedentes de cardiopatia isquémica, duplamente antiagregado, que recorreu ao hospital após episódio de síncope. O exame físico foi inespecífico e os seus exames apenas revelaram anemia ferropénica (9,2 gr/dL). A investigação diagnóstica subsequente mostrou um adenoma do cólon que foi excisado endoscopicamente. Apresentou novo episódio de síncope, associado a descida aguda da hemoglobina (4,5 gr/dL), sem evidência clínica das perdas hemáticas. Repetiram-se os estudos (endoscópicos e tomografias), que foram negativos. Realizou, entretanto, estudo por videocápsula que revelou uma massa no jejuno, que foi excisada cirurgicamente confirmando o diagnóstico de GIST como a verdadeira causa da anemia e das síncope. Passado um ano, o doente encontra-se sob *imatinib*, sem qualquer evidência de recidiva. Faz-se uma breve revisão do tema a propósito deste caso clínico. O diagnóstico do GIST nem sempre é linear. Manifestam-se usualmente por hemorragia gastrointestinal e anemia, sendo maioritariamente detectados em exames endoscópicos ou pela tomografia computadorizada. Sempre que possível, a ressecção cirúrgica completa é o tratamento de eleição, com tratamento adjuvante com *imatinib* em doentes de alto risco. Perante um GIST irressecável ou cuja excisão pode resultar em grande morbidade, o *imatinib* também é usado como neoadjuvante. No caso de doença metastática avançada, o tratamento é feito apenas com inibidores da tirosina-cinase, ficando a cirurgia para algumas das complicações.

Palavras-chave: tumor estroma gastrointestinal, síncope, *imatinib*.

ABSTRACT

Gastrointestinal stromal tumor (GIST) is a rare mesenchymal tumor (0,1-3% of all gastrointestinal tumors), mostly found in the stomach and small intestine. In most cases, GIST is caused by a gain-of-function mutation in *KIT* gene, resulting in an abnormal proliferation of interstitial Cajal cells. We report the case of a 74-year-old man, with a history of ischemic heart disease, under double antiaggregation, who went to the hospital after an episode of syncope. Physical examination was unremarkable, and his exams only revealed an iron deficiency anemia (9.2 g/dL). Subsequent diagnostic investigation showed a colon adenoma that was excised endoscopically. He presented a new episode of syncope, associated with acute hemoglobin decrease (4.5 g/dL), without clinical evidence of blood loss. We repeated the studies (endoscopic and tomography), which were negative. In the meantime, a videocapsule study was performed, which found a mass in the jejunum, surgically excised, confirming the diagnosis of GIST; the true cause of anemia and syncope. One year passed, our patient is taking *imatinib*, with no evidence of relapse. Presenting this case report, we do a brief review of this theme. The diagnosis of GIST is not always linear. They are manifested mainly by gastrointestinal hemorrhage and anemia, and most are detected in endoscopic examinations or by computed tomography. Whenever possible, complete surgical resection is



the treatment of choice, with adjunctive treatment with *imatinib* in high-risk patients. In the presence of an unresectable GIST or whose excision may result in great morbidity, *imatinib* may also be used as neoadjuvant. In advanced metastatic disease, treatment is only done with tyrosine-kinase inhibitors, and surgery is done only for some of the complications.

Keywords: *gastrointestinal stromal tumor, syncope, imatinib.*

INTRODUCTION

Gastrointestinal stromal tumor (GIST) is a mesenchymal tumor arising from the interstitial cells of Cajal, which have a pacemaker function in the *muscularis propria* of the gastrointestinal (GI) tract and myenteric plexus, promoting peristalsis.¹ Although being the most common mesenchymal tumor, they only account for 0,1-3% of all GI tumors.² The mean annual incidence is 10-15 cases per million people, with a median age at diagnosis of 60-65 years-old.^{3,4}

Authors present this case report of a GIST, with an atypical presentation, doing a brief review of this subject. The presence of a synchronous colonic adenoma obscured the main diagnosis. The finding of a second tumor in sporadic GIST, albeit rare and usually incidental, is being more frequently found in the literature.⁵

CASE REPORT

Seventy-four-year-old male patient, with history of type 2 diabetes and diffuse arterial disease with important stenosis of visceral and coronary arteries, under double platelet antiaggregation with acetylsalicylic acid 150 mg and clopidogrel 75 mg daily, arrived to the emergency department after an episode of sudden post prandial epigastric pain, followed by syncope. When he regained consciousness, he had an episode of alimentary vomit, with complete pain relief. The physical exam was unremarkable as the patient had a soft, non-tender abdomen, without any palpable masses, and rectal examination was inconspicuous. The first analytic studies showed a microcytic hypochromic anemia (hemoglobin of 9.2 g/dL), with confirmed ferropenia,

with no elevation of troponin. Electrocardiogram (ECG) and 24-hour holter-ECG had no pathological findings and computed tomography (CT) scan was negative for pulmonary embolism.

Endoscopic studies were performed. A 2 cm high-grade dysplasia tubulovillous adenoma was found in the sigmoid colon, which was endoscopically removed without complications.

Ten days after discharge the patient remained asymptomatic and had hemoglobin of 9.1 g/dL. However, three days later, patient had another syncope episode, with a hemoglobin drop to 4.5 g/dL, which led to transfusion support. There was no visible blood loss, either in physical examination and nasogastric intubation. Abdominal CT scan excluded retroperitoneal hemorrhage and repetition of endoscopic studies did not show signs of acute hemorrhage. Afterwards, an endoscopic videocapsule was performed, which displayed a jejunal nodular lesion occupying half of the perimeter of the organ with a central ulceration (image 1).

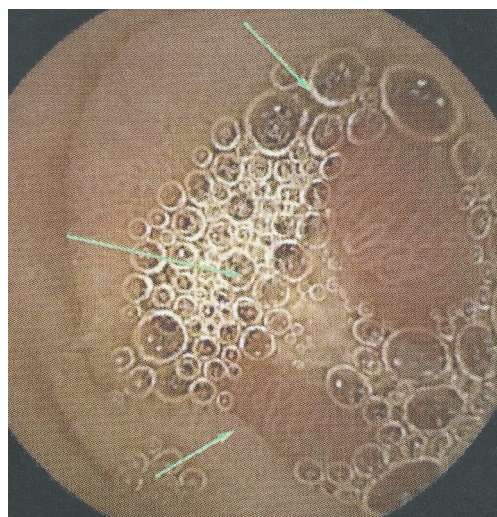


IMAGE 1 – Endoscopic videocapsule – jejunal nodular lesion occupying half of the perimeter of the organ with central ulceration.



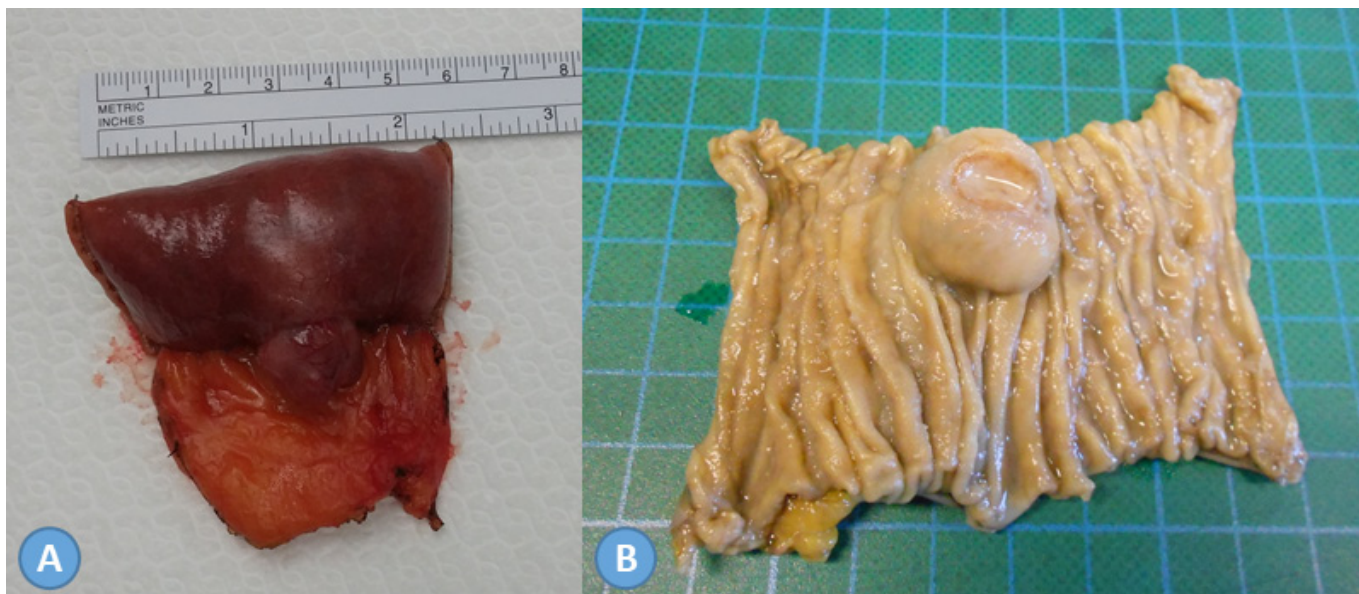


IMAGE 2 – Macroscopic aspect of the surgical specimen: outer view (A); inner view, noting the central ulceration (B).

The patient underwent surgery and, through a mini-laparotomy, segmental jejunal resection was performed (image 2A, 2B). The post-operative period was uneventful, and the patient was discharged four days after the procedure.

Pathology examination revealed a spindle cell type tumor (2,1x2,3 cm) with positive actin, CD117 and CD34, but negative S100, NSE and desmin; with 10 mitosis per 50 high-power fields (HPF), consistent with high-risk GIST. Mutation in exon 11 of *KIT* gene was confirmed (image 3).

The patient remained asymptomatic and began therapy with *imatinib* 400 mg a day. Since the patient had surgery, about a year ago, the surveillance scans show no evidence of reoccurrence of the disease.

DISCUSSION

GIST presents, most commonly, with upper GI bleeding and anemia and sometimes with abdominal pain, early satiety, a palpable mass or constitutional symptoms (fatigue, anorexia and weight loss). However, small bowel GIST may be clinically silent for a long time and present acutely with bleeding or perforation.³

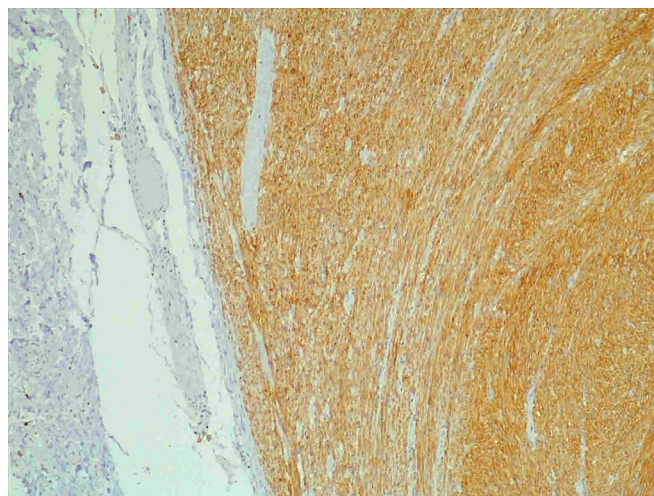


IMAGE 3 – Immunohistochemical – Microscopic view of the tumor with spindle cell patterns, with CD117 positive staining (light brown areas) (x200).

Approximately in one-third of GIST cases, the tumor is found incidentally during surgery or in studies for other diseases.⁶ In this case, syncope was the main symptom: the first episode seemed to be due to a vasovagal response to pain and the second one secondary to acute anemia, even without other clinical evidence.

GIST is more frequently found in the stomach (60%), followed by the small bowel (30%), duodenum (5%), colorectum (4%) and rarely in esophagus and appendix.



Extra-GI locations include omentum, mesentery, retroperitoneum and bladder, where KIT positive mesenchymal cells are found.^{1,7}

GIST is found either in a CT scan or in an endoscopic study as a sub mucosal tumor. Histological diagnosis can be made by ultrasound guided fine-needle aspiration or surgically.^{7,8} For a primary resectable lesion, suspicious for GIST, not requiring neoadjuvant therapy, a preoperative biopsy is not usually needed. It may be useful for unresectable or marginally resectable tumors, because preoperative therapy is needed in those situations, and for excluding diseases that are approached differently (i.e. non-operatively), like lymphomas. Preoperative biopsy may rupture a suspected GIST, therefore risking tumoral cell seeding.⁶

Histologically, there are three types of GIST: spindle cell (70%), epithelioid (20-25%) and mixed (5-10%).¹

The growth and survival of interstitial cells of Cajal depends on stem cell factor, which is the cytokine that is regulated through KIT kinase (or CD117), the protein expressed by the *KIT* gene. CD34 and DOG1 are other markers also present in GIST.¹ Most of GIST (95%) have a gain-of-function mutation in *KIT* – exon 11, which results in ligand-independent kinase activation. However, some tumors lack *KIT* mutations and have mutations in other genes (*PDGFRA*, *BRAF* or *KRAS*).¹ Small bowel GIST is mostly spindle cell type and KIT-positive (about 98%).⁹

The differential diagnosis of GIST includes smooth muscle and neurogenic tumors, fibromatosis, lymphoma and melanoma. Immunohistochemistry is helpful for differentiating them.^{1,3}

Molecular analysis of *KIT* and *PDGFRA* is useful in confirming the diagnosis in dubious cases and in establishing the therapeutic regimen, as tumors with *KIT* exon 11 mutation are much more likely to respond to *imatinib* therapy than tumors with other *KIT* mutations and D842V *PDGFRA* mutation.¹

GIST is usually considered malignant, despite having various levels of aggressiveness. About 10% of patients have metastatic disease at presentation, which is more common in the liver and peritoneum; while lymphatic, bone and extra-abdominal metastasis are rare.^{2,10}

Although some GIST may be found in the context of germline mutations that predispose patients to multiple types of neoplasms, like in gene *NFI*, in the succinate dehydrogenase complex or *KIT*, most of GIST are sporadic. However, it is increasingly reported the synchronous presentation of GIST with other tumors, mostly GI (gastric and colon), pancreatic and hepatic carcinomas, as well as lymphoproliferative disorders, breast, lung or gynecological carcinomas and even kidney neoplasms.^{5,11} Our patient had a synchronous high-grade dysplasia colonic tubulovillous adenoma.

Unlike most tumors, TNM (tumor, node, metastasis) is not used for staging GIST and for risk assessment, instead, other features are used: mitotic index (number of mitosis per 50 HPF), tumor size and primary site.³ The Memorial Sloan Kettering Cancer Center developed a nomogram using those features to predict the risk for tumor recurrence after surgical excision of a localized primary GIST.¹² Using this tool in our case, the probability of recurrence-free survival is about 26% at 2 years and 7% at 5 years¹. Overall, gastric GIST has a lower risk of recurrence, as well as tumors with a mitotic index of 5 or lower and GIST smaller than 5 cm.^{3,4,9} Small bowel GIST have a more malignant progression than gastric ones, with a 40-50% tumor-related mortality.⁹

Complete surgical tumor excision is the only potentially curative treatment, despite almost half the high-risk patients have recurrent or metastatic disease after resection. Regarding localized disease amenable to resection, all GIST 2 cm or greater should be excised. Since small bowel and colonic GIST are more aggressive, these tumors should be resected regardless of the size.¹³ Surgery should be followed by adjuvant therapy with tyrosine kinase inhibitors (TKI), such as *imatinib* for at least 3 years in high-risk patients.^{3,4,13} Disease progression or reoccurrence under *imatinib* or intolerance to its side effects is the indication for *sunitinib* treatment.⁸ For tumors resistant to both *imatinib* and *sunitinib*, *regorafenib* is an option.¹³

¹ Tool available at https://www.mskcc.org/nomograms/gastrointestinal/stromal_tumor



If a tumor-free margins resection is unlikely without major sequelae or if there is a high risk of intraoperative tumor rupture or bleeding, neoadjuvant therapy should be considered.³ *Imatinib* should be stopped 24 hours before surgery and therapy can be restarted when the patient starts having a regular diet. Since *sunitinib* interferes with the healing process, it should not be taken 5 to 7 days before surgery until two weeks after the procedure.¹³

In metastatic disease, *imatinib* treatment should be carried on indefinitely because therapy interruption is generally followed by relapse.¹⁴ The role of surgery in metastatic disease is more limited, but it has been shown that it may improve patient outcome in stable and in TKI-responsive metastasis and in progressive oligometastatic disease. For multifocal progressive disease, surgery should not be performed, unless complications, such as bleeding, obstruction or perforation are present.¹³

GIST follow-up should be done with abdominopelvic contrast-enhanced CT scan or magnetic resonance imaging. For low risk GIST, annual CT scan abdomen is recommended for 5 years. For high-risk patients, during *imatinib* treatment, it is advised abdominopelvic CT scan every 6 months and every 3-4 months for the

first 2 years after discontinuation of therapy and then every 6-12 months for 10 years.^{8,10}

CONCLUSION

Ferropenic anemia without an obvious cause in the elderly patient should raise the suspicion for a gastrointestinal neoplasm. In this case, GIST was the cause of an occult gastrointestinal bleeding with syncope as presentation, but without clinical evidence of blood loss, which diffculted the diagnosis. Surgery is the only potentially curative treatment for this disease and, many times, it serves diagnostic purposes as well, as preoperative biopsy is not always possible or even indicated.

ACKNOWLEDGEMENTS

We thank surgical team, Júlio Ribeiro and Carlos Martins, for performing the surgical resection of the tumor and pathologist Isabel Serrano, for the analysis of the pathological specimen.



REFERENCES

1. Zhao X, Yue C. Gastrointestinal stromal tumor. *J Gastrointest Oncol* 2012;3(3):189-20.
2. Ertuk M, Van Der Abbeele A. Infrequent Tumors of the Gastrointestinal Tract Including Gastrointestinal Stromal Tumor (GIST). *PET Clin 3* (2008) 207-215.
3. Judson I, Bulusu R, Seddon B, et al. UK clinical practice guidelines for the management of gastrointestinal stromal tumors (GIST). *Clin Sarcoma Res* (2017) 7:6.
4. Rutkowski P, Przybyl J. Extended Adjuvant Therapy with Imatinib in Patients with Gastrointestinal Stromal Tumors. *Mol Diagn Ther* (2013) 17:9-19.
5. Efsthios P, Athanasios P, Papaconstantinou I, et al. Coexistence of a gastrointestinal stromal tumor (GIST), and colorectal adenocarcinoma. A case report. *World J Surg Oncol* 2007, 5:96.
6. Keung E, Raut C. Management of Gastrointestinal Stromal Tumors. *Surg Clin N Am* 2017; 97: 437-452
7. Nishida T, Blay J, Hirota S. The standard diagnosis, treatment and follow-up of gastrointestinal stromal tumors based on guidelines. *Gastric Cancer* (2016) 19:3-14.
8. Lanke G, Lee J. How to best manage gastrointestinal stromal tumor. *World J Clin Oncol* 2017 April 10; 8(2): 135-144.
9. Miettinen M, Lasota J. Gastrointestinal stromal tumors: pathology and prognosis at different sites. *Semin Diagn Pathol* 2006;23:70-83.
10. Joensuu H, Martin-Broto J, Nishida T, et al. Follow-up strategies for patients with gastrointestinal stromal tumour treated with or without adjuvant imatinib after surgery. *Eur J Cancer* 2015; 51: 1611-1617
11. Hechtman J, DeMatteo R, Nafa K, et al. Additional Primary Malignancies in Patients with GIST: A Clinicopathologic Study of 260 Patients with Molecular Analysis and Review of the Literature. *Ann Surg Oncol*. 2015; 22(8):2633-9
12. Chok A, Goh B, Koh Y, et al. Validation of the MSKCC Gastrointestinal Stromal Tumor Nomogram and Comparison with Other Prognostication Systems: Single-Institution Experience with 289 Patients. *Ann Surg Oncol* 2015; 22: 3597-3605
13. Schrage Y, Hartgrink H, Smith M, et al. Surgical management of metastatic gastrointestinal stromal tumor. *Eur J Surg Oncol* 2018; 44: 1295-1300
14. Mehren M, Liu Y. Randomized Clinical Trials in Gastrointestinal Stromal Tumors. *Surg Oncol Clin N Am* 2017; 26: 545-557

Correspondência:

PEDRO AZEVEDO
e-mail: azeved@hotmail.com

Data de recepção do artigo:

17/08/2018

Data de aceitação do artigo:

12/11/2019

