








MULTIDISCIPLINARY APPROACH TO ACUTE MESENTERIC ISCHEMIA – A SUCCESS CASE

ABORDAGEM MULTIDISCIPLINAR DA ISQUEMIA MESENTÉRICA AGUDA – UM CASO DE SUCESSO

 Oriana NOGUEIRA^{1,2},  José BAIÃO³,  Mariana DUQUE^{1,2},  Vânia OLIVEIRA^{2,4},
 Luís ANTUNES^{2,4}, Joana MOREIRA^{2,4},  Pedro OLIVEIRA^{1,2},  André LÁZARO^{1,2,5}

¹ General Surgery Unit, Centro Hospitalar e Universitário de Coimbra (CHUC), Coimbra, Portugal

² Clinical Academic Center of Coimbra, Coimbra, Portugal

³ General Surgery Unit, Centro Hospitalar do Baixo Vouga, Aveiro, Portugal

⁴ Angiology and Vascular Surgery Unit, Centro Hospitalar e Universitário de Coimbra (CHUC), Coimbra, Portugal

⁵ Coimbra Institute for Clinical and Biomedical Research (CBR) area of Environment Genetics and Oncobiology (CIMAGO), Faculty of Medicine, University of Coimbra, Coimbra, Portugal

Correspondence: Oriana Nogueira (oriana.nog83@gmail.com)

Received: 24/01/2024

Accepted: 12/04/2024

Published online: 27/07/2024

ABSTRACT

Introduction: Acute Mesenteric Ischemia (AMI) is a surgical emergency that results from interruption of mesenteric vascular flow. With a multifactorial etiology, it is often associated with embolic occlusion of the superior mesenteric artery (SMA). Late diagnosis and patient co-morbidities usually lead to high surgical morbidity and mortality rates.

Case Report: We describe a case of a 57-year-old man, admitted to the Emergency Department (ED) with acute abdominal pain and vomiting. After clinical examination and computerized tomography (CT) scan imaging the subject was diagnosed with mesenteric ischemia. The patient underwent emergent surgery, with a multidisciplinary approach including general surgery and vascular surgery teams. **Conclusion:** Early diagnosis associated with adequate resuscitation was essential in the patient's prognosis.

Keywords: acute mesenteric ischemia, mesenteric revascularization, bowel resection

RESUMO

Introdução: A isquemia mesentérica aguda (IMA) é uma emergência cirúrgica que resulta da interrupção do fluxo vascular mesentérico. Com uma etiologia multifatorial, está frequentemente associada à oclusão embólica da artéria mesentérica superior (AMS). O diagnóstico tardio e as comorbilidades do paciente geralmente levam a altas taxas de morbidade e mortalidade cirúrgica. **Relato de Caso:** Descrevemos o caso de um homem de 57 anos, admitido no Serviço de Urgência (SU) com dor abdominal aguda e vômitos. Após exame clínico e tomografia computadorizada (TC), foi diagnosticada isquemia mesentérica. O paciente foi submetido a cirurgia de emergência, com uma abordagem multidisciplinar que incluiu equipas de cirurgia geral e cirurgia vascular. **Conclusão:** O diagnóstico precoce associado a uma ressuscitação adequada foram essenciais para o prognóstico do paciente.

Palavras-chave: isquemia mesentérica aguda, revascularização mesentérica, resseção intestinal.



INTRODUCTION

Acute Mesenteric Ischemia (AMI) is a surgical emergency, which occurs when there is interruption of mesenteric vascular flow. It is a rare disease, responsible for approximately 1% of cases of acute abdomen and 0.1% of hospital admissions, preferentially committing the elderly population^{1,2}.

With a multifactorial etiology, it is frequently associated with arterial thromboembolism and atherosclerotic disease. The clinical presentation is variable and nonspecific, which makes its early recognition and diagnosis difficult, conditioning the delay in treatment, often fatal for the prognosis of these patients, with mortality rates peaking at 50-80%^{3,4,5}.

It is essential that the surgeon is knowledgeable about the pathology (clinical, risk factors, epidemiological context) and has a high level of suspicion, in order to allow a timely diagnosis and early targeted therapy and thus reducing the associated morbidity and mortality.

CASE REPORT

A 57-year-old male patient, previously healthy, was referred to the ER for vomiting and sudden abdominal pain in the right hypochondrium (RH) and epigastrium (EG) with 5 hours of evolution. On clinical examination, the patient was restless, hemodynamically stable, afebrile, with a depressible abdomen, painful on palpation in the RH and EG, without tenderness or voluntary guarding. Analytically, the highlights were leukocytosis $15 \times 10^9/L$ and glycemia 584mg/dL, with normal amylase, lipase, and troponin. Arterial blood gas with acidosis and lactacidemia of 3mmol/L. Abdominal ultrasound, chest and abdominal X-ray were normal.

Faced with an initial diagnosis of diabetes (previously unknown), with ketoacidosis and worsening pain, abdominopelvic computerized

tomography angiography (CTA) was requested to exclude macro/microvascular complications. The abdominopelvic CTA revealed total occlusion of the superior mesenteric artery (SMA) about 3cm after its emergence, and small segments of the small bowel showed no contrast enhancement, highly suggestive of ischemia (figure 1).

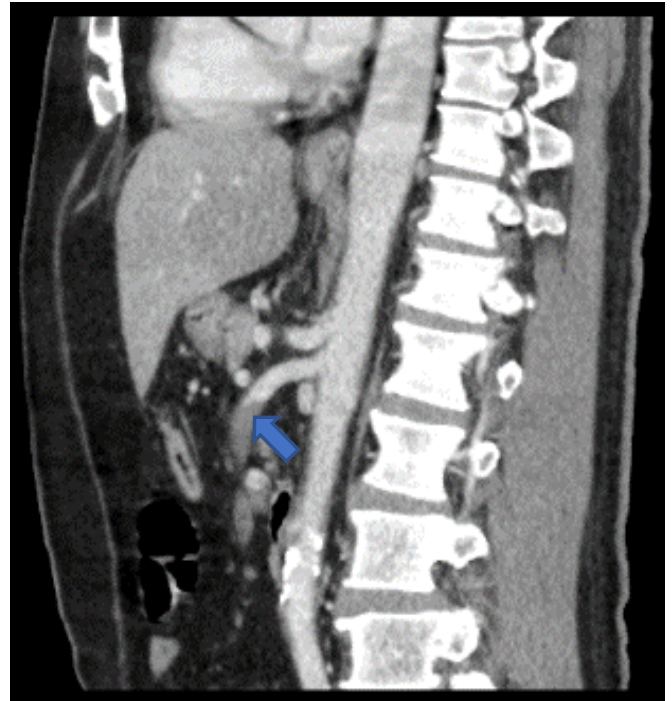


FIGURE 1: CT (sagittal view) – Total occlusion of the SMA 3cm after its emergence (blue arrow)

Simultaneously to the diagnostic investigation, measures were taken to stabilize the patient: correction of hyperglycemia, fluids, analgesics, broad-spectrum antibiotic and therapeutic dose of intravenous heparin. The patient was monitored and a bladder catheter was placed to control urinary output.

The case was discussed between the General Surgery and Vascular Surgery teams, and the patient was taken to the operating room. The patient underwent exploratory laparotomy. Intraoperatively, cyanosis of the right colon (RC) and some small bowel



(SB) segments was detected, without necrosis or perforation. The Vascular Surgery team performed an embolectomy of the SMA (figure 2 and 3).

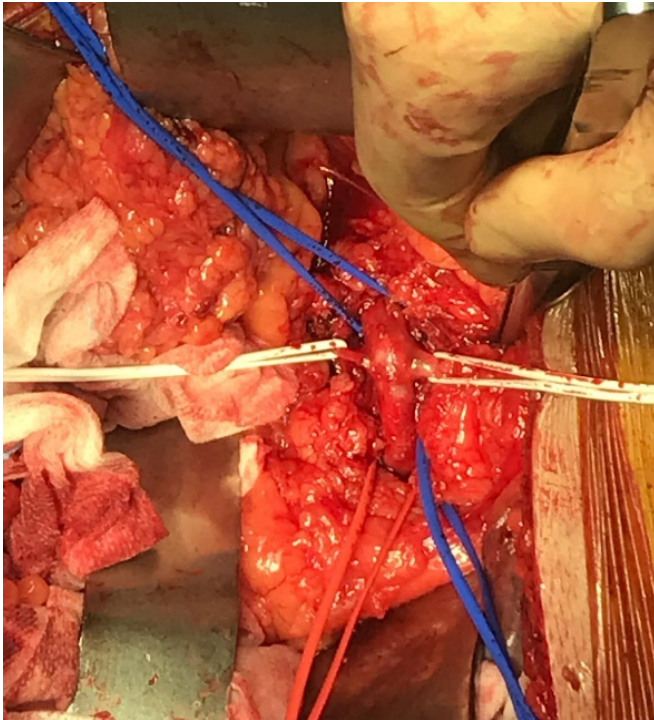


FIGURE 2 AND 3: SMA isolation; transverse arteriotomy and Fogarty embolectomy

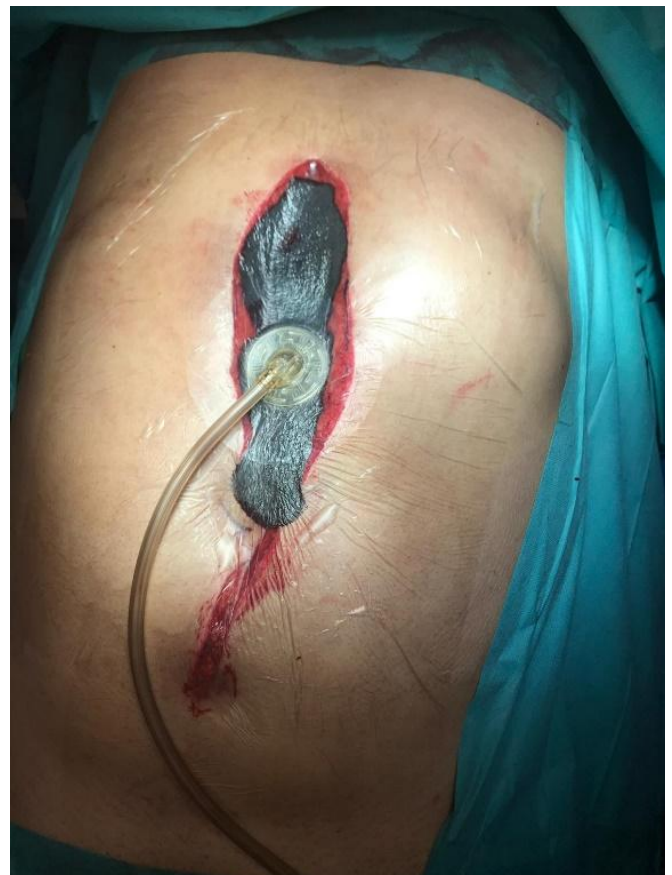

FIGURE 4: Vacuum-assisted laparostomy.

After revascularization, there was reversal of cyanosis in the right colon and most of small bowel but doubts persisted as to the intestinal viability of the first jejunal segment.

A vacuum-assisted laparostomy was placed to allow for an early second-look. Patient was admitted to the Intensive Care Unit (ICU) with a therapeutic dose of heparin and aminergic support. Laparostomy was reviewed at 48h, and there was need for segmental enterectomy with hand-sewn anastomosis. Definitive abdominal wall closure was performed (figures 5 and 6).

The patient remained in the ICU for 10 days. The patient was discharged home on the 15th postoperative day, treated with anticoagulants and referred to several outpatient appointments: General Surgery, Vascular Surgery, Internal Medicine and Immunohemotherapy for an etiological



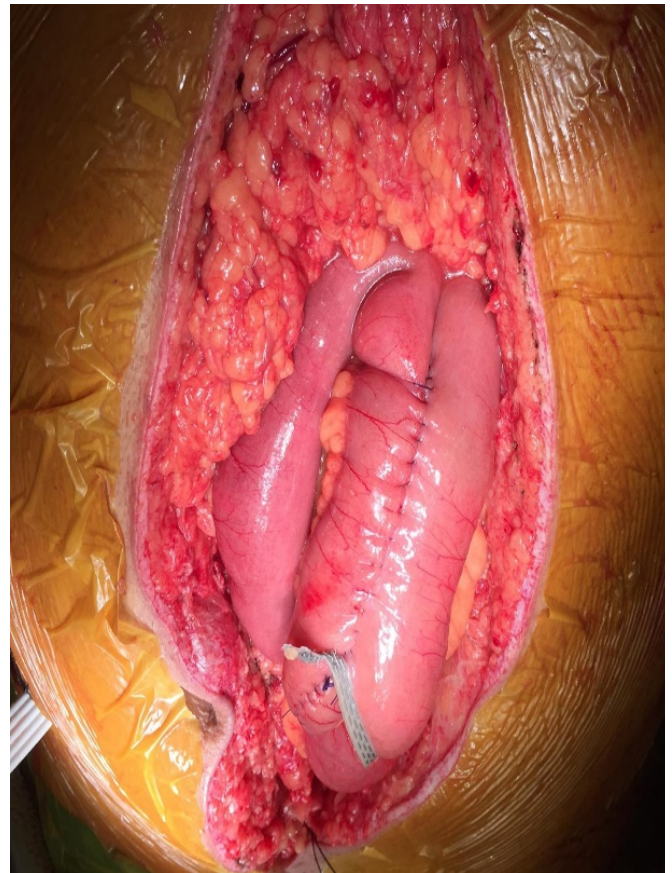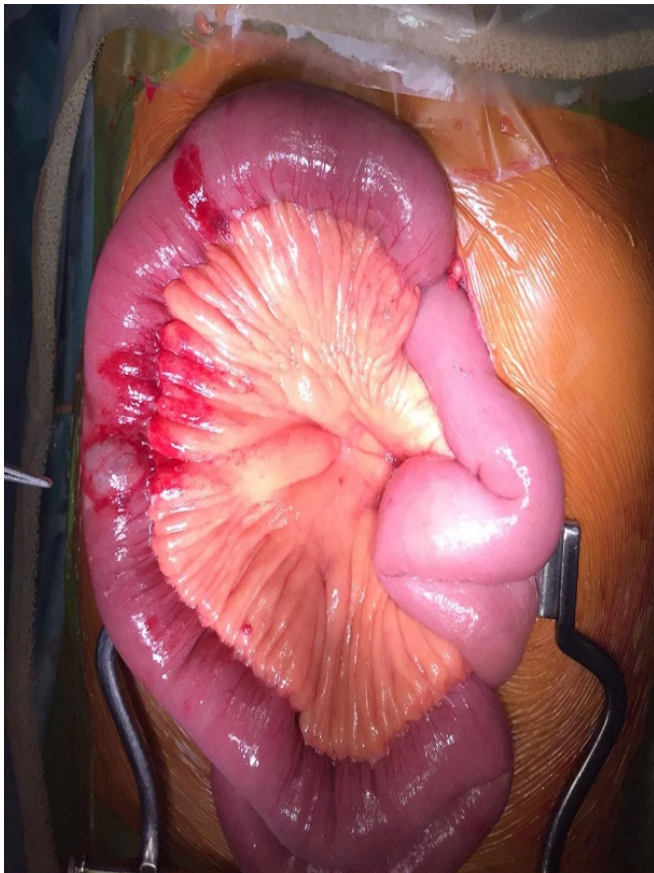


FIGURE 5 AND 6: Marked edema and thickening of the first 50cm of jejunum, followed by a zone of irreversible ischemia and pre-perforation; jejunum-jejunal anastomosis, hand-sewn with 3/0 vicryl

study. From the outpatient study, no evidence of atherosclerosis, structural abnormalities, arrhythmias or coagulopathies was detected. After one year of follow-up, the patient is faring well, with no new episodes.

DISCUSSION

AMI is a life-threatening surgical emergency for the patient. It develops mainly due to four physiological mechanisms: acute arterial embolism (50%), acute arterial thrombosis (15-25%), non-occlusive mesenteric ischemia (25%), and mesenteric venous thrombosis (5-15%)⁵. The SMA appears as the most frequently affected artery, being occluded in 67% of cases.

Several risk factors have been associated with AMI, which vary according to its etiology. Atrial fibrillation (AF), ischemic heart disease, valvular disease and structural heart defects are often related to embolic etiology. On the other hand, AMI of thrombotic etiology usually occurs in association with atherosclerotic disease⁵.

In this case, we think that the most likely etiology for the ischemia was embolic; however, what caused the embolism remains unclear. The cardiac study performed (transesophageal cardiac ultrasound, electrocardiogram and holter) were normal; however, given the absence of other findings in the complementary study performed, we believe that a still undiagnosed paroxysmic arrhythmia may have been the causative factor of the embolism. On the other hand, the thrombotic etiology seems unlikely,



since there were no signs of atherosclerosis in the imaging studies and the most frequent location of occlusion due to thrombosis is the bone.

Abdominal pain is the most frequent symptom associated with AMI, usually of high intensity and disproportionate to the physical examination findings. It may be absent in up to 25% of cases, depending on the etiology. Altered bowel movements, nausea, vomiting, and abdominal distension may also coexist. Abdominal examination may be uneventful, with peritoneal signs appearing only at a later stage when ischemia progresses⁶.

The etiologic diversity associated with nonspecific symptoms makes the diagnosis of AMI challenging, and a high level of suspicion is essential to avoid delays in diagnosis and treatment.

AMI usually progresses with leukocytosis and in more advanced stages, with metabolic acidosis and increased lactate; however, its importance is limited, as it does not make or exclude the diagnosis¹.

CTA is the gold-standard imaging test for AMI diagnosis, with high sensitivity and specificity (93% and 96%, respectively)⁷. It allows detection of ischemic changes in the affected bowel segment and respective mesentery, as well as identification of the cause of ischemia. On the other hand, it allows the exclusion of other differential diagnoses of acute abdominal pain⁷.

In parallel with the diagnostic investigation, it is crucial to initiate appropriate resuscitation measures early on, in order to stabilize the patient and treat the systemic inflammatory response resulting from the ischemic lesion, since these have an impact on patient's prognosis. These measures include: fluid replacement, correction of hydroelectrolytic imbalances, broad spectrum antibiotic therapy, anticoagulation, analgesia⁸, among others. Continuous patient monitoring and of urine output are equally important.

When diagnosed early, AMI may be treatable. However, its treatment is still being studied in an attempt to clarify the most appropriate approach. Currently, the therapeutic option seems to depend

more on the surgeon's expertise and institutional preference⁹.

Given the complexity of the pathology, its approach should ideally be multidisciplinary (General Surgery, Vascular Surgery, Interventional Radiology), with the goal of early revascularization of the mesenteric flow, in order to minimize morbidity and mortality.

The surgical approach through a median laparotomy remains the most commonly used approach and is preferably indicated in cases of AMI complicated by peritonitis or intestinal necrosis. It consists of an exploratory laparotomy to assess intestinal viability (severity and extent), followed by revascularization⁵.

Revascularization can be obtained by endovascular, surgical or hybrid approach; its choice will depend on the hemodynamic stability of the patient, presence or absence of peritonitis and if intestinal necrosis is suspected¹⁰. With the advances in minimally invasive techniques, endovascular revascularization has gained ground in recent years, being associated with fewer perioperative complications and lower morbidity and mortality^{2,8}. However, it should be reserved for cases of early and uncomplicated AMI, since this approach does not allow for the evaluation of intestinal viability and, as such, should not delay treatment, otherwise it may worsen the prognosis. Most studies advocate that revascularization should be performed first and only afterwards resection of non-viable tissues (because there may be doubt about intestinal viability), except in cases of evident necrosis or perforation^{1,11}.

On the other hand, laparoscopy may have a role (in selected cases) in the initial assessment of intestinal viability, and it can also be used as a complementary means when endovascular revascularization is chosen⁵.

Open thromboembolectomy is a frequently used technique with rapid restitution of mesenteric flow; however, in AMI of thrombotic etiology it may be necessary to perform an endarterectomy or bypass. After revascularization and when there is



doubt about bowel viability, the patient should be placed on laparostomy and a second-look surgery scheduled between 24-48 hours for reassessment¹².

According to a meta-analysis by Salsano et al [9], the endovascular revascularization strategy is shown to offer advantages in terms of in-hospital morbidity and mortality in cases of arterial occlusive AMI, results that have been corroborated by other studies^{13,14}. However, additional randomized studies will be necessary to confirm these results.

The timing between diagnosis and revascularization is crucial for the success of the intervention and the patient's prognosis. In our case, we believe that the fact of being a relatively young person, without comorbidities, associated with clinical suspicion, early diagnosis and intervention, were crucial for the success of the intervention.

CONCLUSION

AMI usually has a poor prognosis and a high mortality rate. In this case, early diagnosis, adequate resuscitation and timely multidisciplinary approach were of paramount importance for the patient's prognosis.

A high level of suspicion is the key to therapeutic success.

Acknowledgments: None

Funding: None

Conflicts of interest: None

Informed consent was declared by the authors

REFERENCES

1. Kuhn F, Schiergens T, Klar E. Acute mesenteric ischemia. *Visc Med.* 2020;36;256-262.
2. Lim S, Halandras P, Bechara C, Aulivola B, Crisostomo P. Contemporary management of acute mesenteric ischemia in the endovascular era. *Vasc Endovascular Surg.* 2019; 53(1);42-50.
3. Clair D & Beach J. Mesenteric ischemia. *N Engl J Med.* 2016;374(10);959-968.
4. Luther B, Mamopoulos A, Lehmann C, Klar E. The ongoing challenge of acute mesenteric ischemia. *Visc Med.* 2018; 34(3);217-223.
5. Bala M, Catena F, Kashuk J, De Simone B, Weber D, Sartelli M, et al. Acute mesenteric ischemia: update guidelines of the World Society of Emergency Surgery. *World J Emerg Surg.* 2022;17(54).
6. Karkkainen J & Acosta S. Acute mesenteric ischemia (part I) – Incidence, etiologies, and how to improve early diagnosis. *Best Pract. Res. Clin. Gastroenterol.* 2017;31;15-25.
7. Hawthoen B & Ratnam L. Acute mesenteric ischaemia: imaging and intervention. *Clinical Radiology.* 2020;75(5);398.E19-398.E28.
8. Savlania A & Tripathi R. Acute mesenteric ischemia: current multidisciplinary approach. *The Journal of Cardiovascular Surgery.* 2017;58(2);339-350.
9. Salsano G, Salsano A, Sportelli E, Petrocelli F, Dahmane M, Spinella G, et al. What is the best revascularization strategy for acute occlusive arterial mesenteric ischemia: systematic review and meta-analysis. *Cardiovasc Intervent Radiol.* 2018; 41; 27-36.
10. Karkkainen J & Acosta S. Acute mesenteric ischemia (Part II) – Vascular and endovascular approaches. 2017;31(1);27-38.
11. Björck M, Koelemay M, Acosta S, Goncalves F, Kolbel T, Kolkman J. Editor's Choice – Management of the diseases of mesenteric arteries and veins: clinical practice guidelines of the European Society of Vascular Surgery (ESVS). *Eur J Vasc Endovasc Surg.* 2017;53(4);460-510.
12. Blauw J, Bulut T, Oderich G, Geelkerken B. Mesenteric vascular treatment 2016: from open surgical repair to endovascular revascularization. *Best Pract. Res. Clin. Gastroenterol.* 2017; 35;75-84.
13. Zhao Y, Yin H, Yao C, Deng J, Wang M, Li Z, Chang G. Management of acute mesenteric ischemia: a critical review and treatment algorithm. *Vasc Endovasc Surg.* 2016;50(3);183-192.
14. Faragy M, Hadi A, Eisha M, Bashaeb K, Antoniou G. Systematic review and meta-analysis of endovascular treatment for acute mesenteric ischaemia. *Vascular.* 2017;25(4); 430-438.

